

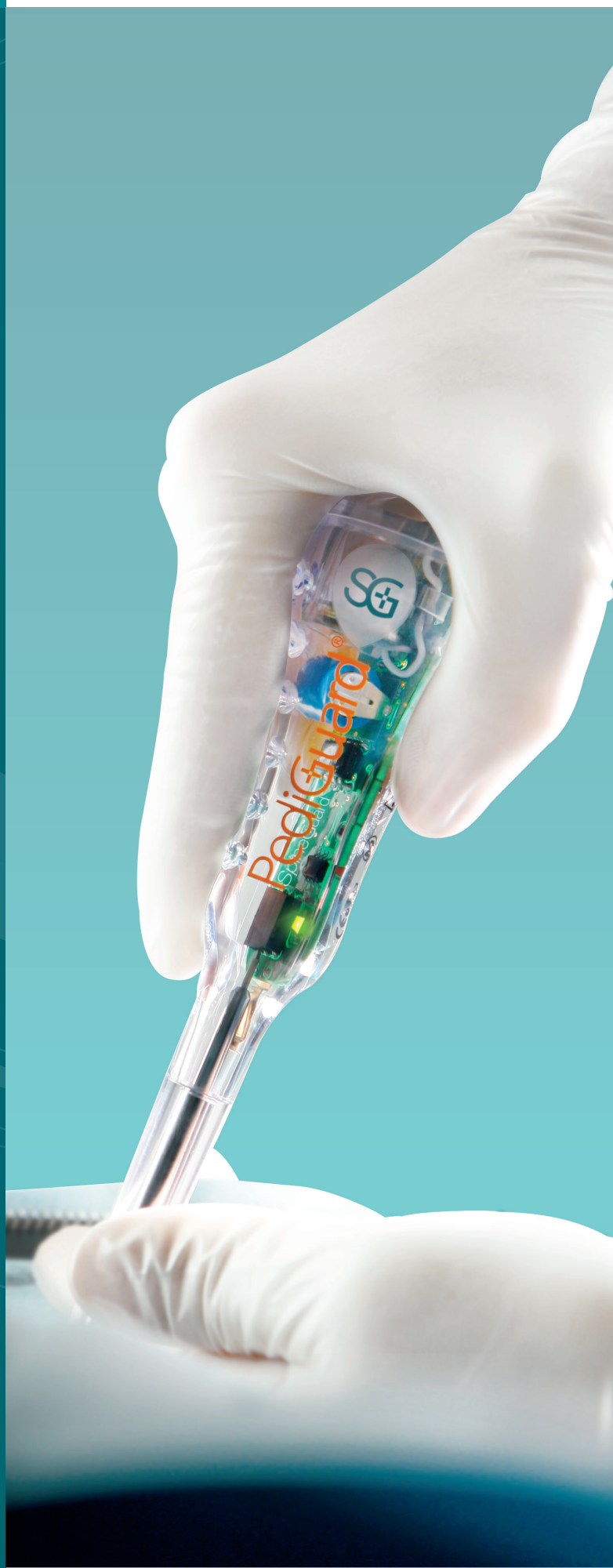Case Report

Severe neuromuscular
scoliosis with marked
rotational deformity

Peter G. Gabos, MD

Co-Director,
Spine and Scoliosis Center
Nemours/Alfred I. duPont Hospital for Children
Wilmington, Delaware, USA

SpineGuard[®]
Making spine surgery safer



Case

10 year old female with spastic quadriplegic cerebral palsy presented as non-ambulatory with bronchopulmonary dysplasia, seizure disorder, tracheostomy, G-tube, and frequent pneumonia. At the time of presentation, she was no longer able to tolerate upright positioning and managed supine.

Preoperative images (Fig. 1a and 1b) revealed severe and rigid left thoracolumbar scoliosis, measuring 160 degrees, marked pelvic obliquity, pain and skin breakdown due to right costo-pelvic impingement, painless hip range of motion from full extension to 100 degrees flexion despite late stage acquired spastic hip dysplasia.

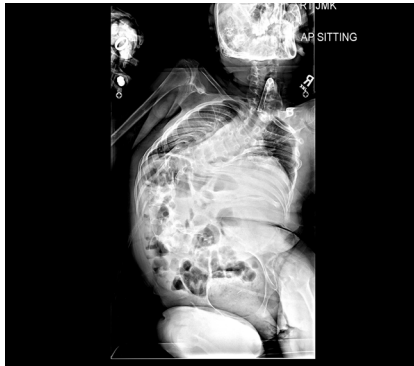


Fig. 1a

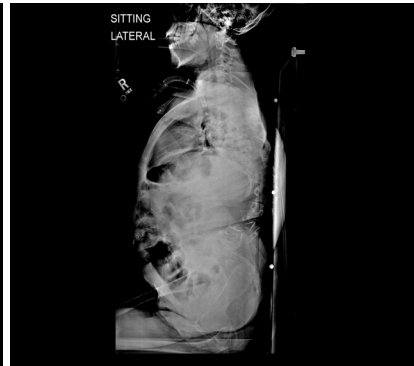


Fig. 1b

Treatment Goals

Restore spinopelvic balance to regain sitting ability, reduce pain from costo-pelvic impingement and severe spinal deformity, maximize respiratory and cardiac function, and improve burden of care.

Surgical Plan

In the first stage, a left anterior release via 10th rib thoracoabdominal approach (Fig. 2) was performed with T9 to L4 anterior longitudinal ligament release and complete discectomies, L1 corpectomy and pedicle resection, and T11 to L3 lateral closing wedge vertebral body osteotomies. Patient underwent 3 weeks of continuous inpatient halo-gravity traction. She was able to be positioned upright for extended periods throughout the day.

In the second stage, posterior instrumented spinal fusion was performed from T2 to pelvis with completion of L1 vertebral column resection (VCR) using segmental pedicle screw fixation, dual titanium rods, sacral alar-to-iliac (SAI) screws and single cross-connector.

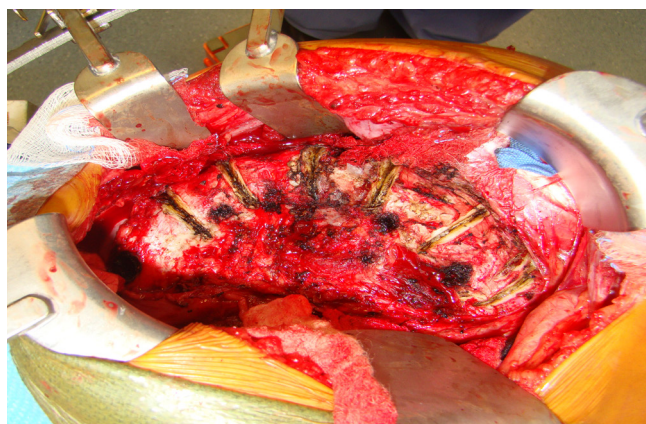


Fig. 2

Pedicle Preparation Instrumentation: PediGuard[®] probe

The PediGuard probe with DSG™ (Dynamic Surgical Guidance) Technology is a stand-alone, pedicle preparation instrument requiring no additional equipment. It differentiates between tissue types (cancellous, cortical or soft tissue) based on their electrical conductivity via a bipolar sensor embedded at the tip of each device. The probe provides real-time audible and visual signals to the surgeon, allowing for anticipation of potential cortical wall breaches and redirection as necessary.



Fig. 3

Pedicle Preparation Technique

All of the pedicles were cannulated using a PediGuard Curved XS probe and free-hand technique. The marked apical vertebral rotation of greater than 90 degrees would have made use of fluoroscopy or CT navigation difficult. Use of the PediGuard probe without adjunct imaging allowed the surgeon to stand in a comfortable position during pedicle drilling, with less chance of contamination of the surgical field or radiation exposure from image guidance (Fig. 4). After all screws were placed, an intraoperative low-dose CT scan was performed to verify screw trajectory and length. No screw adjustments were necessary (Fig. 5). The VCR at L1 was completed, utilizing temporary rods to stabilize the resected segment, followed by placement of both spinopelvic fixation rods, utilizing cantilever and compressive forces (Fig. 6).

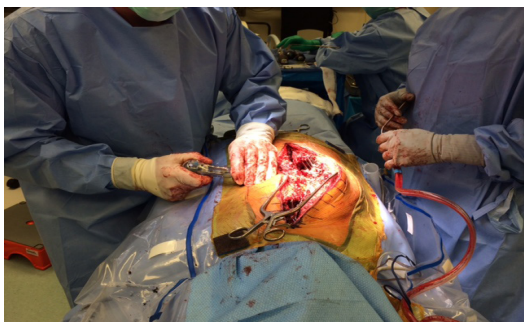

Fig. 4

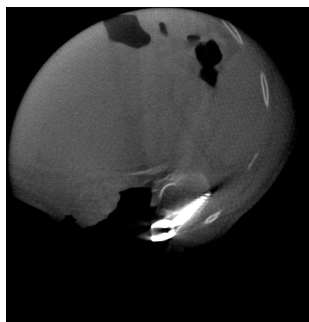


Fig. 5

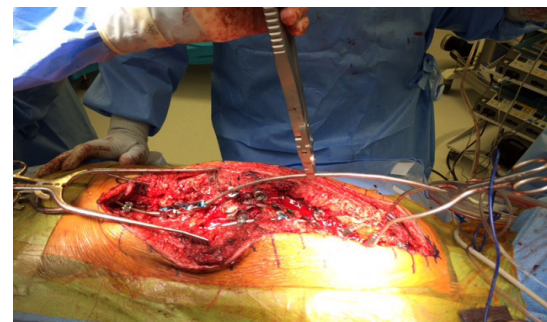

Fig. 6

Postoperative Follow-up

Patient was allowed to sit up in her wheelchair on postoperative day 2 and discharged from the hospital on postoperative day 7. Six weeks after surgery, radiographs confirmed stable instrumentation and satisfactory restoration of spinopelvic balance. The patient was able to sit comfortably throughout the day in her wheelchair for the first time in over 12 months (Fig. 7a and 7b).

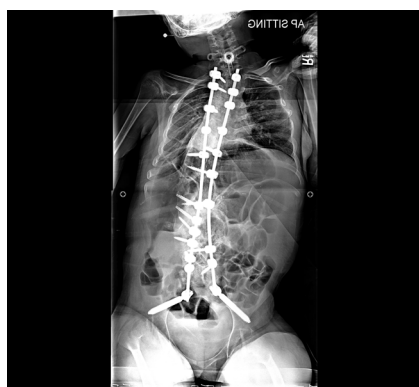

Fig. 7a

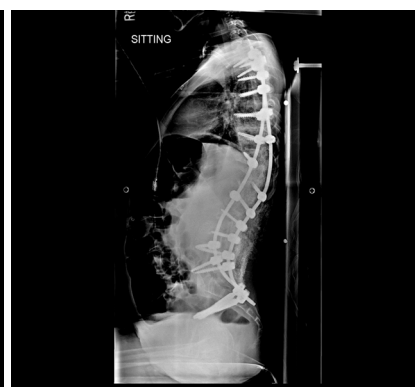

Fig. 7b



DSG™ Technology:
Simple.
Accurate.
Smart.

SpineGuard®
Making spine surgery safer

www.spineguard.com

SpineGuard® S.A.
10, Cours Louis Lumière
94300 Vincennes, France
Phone: +33 1 45 18 45 19
Fax: +33 1 45 18 45 20

SpineGuard® Inc.
1388 Sutter Street, Suite 510
San Francisco, CA 94109 – USA
Phone: +1 415 512 2500
Fax: +1 415 512 8004

CE 0123

Caution: See package insert for labeling limitations, intended uses, relevant warnings, precautions, side effects and contraindications. Federal (USA) law restricts the sale and use of this device to a prescription of a physician.